

# Treatment of cervical intraepithelial neoplasia (CIN)

Because current screening tests (cytology, oncogenic HPV testing, and visual inspection methods) are not specific for cervical precancer, treatment methods need to be effective but also minimally damaging and uncomplicated.

Treatment methods of actual or suspected CIN should be both effective and safe. *Effective* treatment of CIN implies eradicating the TZ and reducing risk of cancer to nearly zero. *Safe* treatment implies reducing the risk of complications to an absolute minimum.

At the outset, the patient should be counselled about the need for treatment, the risks of the procedure, and the risk of not treating the lesion, as well as the need for follow-up and how this should be performed. The decision to treat should not be automatic and should not depend exclusively on the results of

an individual screening or diagnostic test but should take into account the individual case characteristics, which may modify the risk of progression to cancer and the need to treat as well as the relative risks of treatment. Relevant case characteristics include age, parity, previous treatment, fertility aspirations, likelihood of default from follow-up, HPV status, and any other available biomarker triage test results.

Safe treatment will mean a preliminary colposcopic examination by a properly trained colposcopist with adequate documentation of findings in a structured format (see Annex 2). It should record the TZ type, the adequacy of the examination, and an objective diagnostic score, for example the Swede score (Strander et al., 2005) (see Annex 4). Ideally, if the treatment advised is a destructive method, there should be sufficient

biopsy material for an accurate diagnosis. If the treatment is excisional, then it should be performed under binocular colposcopic guidance, to minimize excising excessive or insufficient normal tissue (Carcopino et al., 2013) and inflicting minimal artefactual damage, so that an adequate histology report may be generated and so that the cervical wound is not excessively damaged.

Treatment should accomplish complete eradication of the TZ and not only the lesion. It should ablate the TZ, the whole TZ, and, ideally, nothing but the TZ.

Whether the TZ is being excised or destroyed, ablation to a depth of 7 mm is considered optimal (Shafi et al., 2006). This is because the deepest gland crypt can contain CIN as low as 4 mm (Anderson and Hartley, 1980), and destroying to 7 mm gives a sufficient degree of safety.

## 11.1 Excision or destruction of the transformation zone

The eradication of CIN may be achieved by excision or destruction. There are advantages to each, and either may be achieved using different techniques. Table 11.1 lists the different techniques currently in use and the circumstances where they may be appropriate choices of treatment. The advantages and disadvantages of destructive therapy are listed in Table 11.2. Where facilities allow, treatment should probably be excisional using electrosurgery. Most authorities consider excision to be superior to destruction, because it is possible to perform histological examination of the excised TZ, whereby the grade of abnormality can be determined more accurately, cancer may be ruled out, the completeness of excision can be confirmed, and the dimensions of the excised tissue can be calculated. Also, histological examination will sometimes recognize glandular disease, where present. The excision margin status (i.e. involved with CIN or not) and the size of the TZ will also be revealed, and these are important prognostic indicators for the risk of future pregnancy-related complications. Finally, histological examination allows the colposcopist to audit their own diagnostic acumen in terms of both the diagnosis and the geographical limits of the TZ.

LLETZ/LEEP should usually be performed in a clinic with access to resuscitation facilities. Also, if excision is to be used as a method of treatment, it implies histological examination of the extirpated tissue by a pathologist. Whether or not a pathologist is available, when the lesion is partially endocervical, these lesions need to be treated by way of an excisional technique. For high-grade lesions, excision may often be performed at the first visit, providing

that the patient is fully informed, that there is no disparity between the referral cytology and the colposcopic assessment, and that the TZ is sufficiently small and accessible (i.e. type 1 or shallow type 2 TZ). For every other circumstance, there is no urgency about management, providing that the risk of default from follow-up attendance is low.

## 11.2 Pre-treatment conditions

Ideally, every treatment should be preceded by an adequate, comprehensive colposcopic examination, whereby the examination may determine the type and size of the TZ and

recognize or rule out cancer, microinvasive disease, or precancer as well as assessing the grade of abnormality suspected by the screening test. Once the decision to treat has been made, it is necessary to choose an appropriate method of treatment. The conditions that should be met before performing destructive therapy are detailed in Table 11.3. These conditions apply where facilities allow.

## 11.3 Destructive methods

A variety of energy sources have been used to destroy the TZ in women with suspected CIN. These

**Table 11.1. Treatment choices for CIN**

Technique	Recommendation
<b>Excision</b>	
LLETZ/LEEP	Universal application
Laser excision	Universal application
SWETZ or NETZ	Some type 2 or type 3 transformation zones Glandular disease Suspicion of microinvasion
Hysterectomy	Rarely appropriate
Cold-knife conization	Suspicion of glandular disease or microinvasion
<b>Destruction</b>	
Thermal coagulation	CIN1 and CIN2 All type 1 transformation zones Some type 2 transformation zones No suspicion of cancer, glandular disease, previous treatment, or uncertainty about the grade of abnormality
Laser ablation	As above
Cryocautery	As above

CIN, cervical intraepithelial neoplasia; LEEP, loop electrosurgical excision procedure; LLETZ, large loop excision of the transformation zone; NETZ, needle excision of the transformation zone; SWETZ, straight wire excision of the transformation zone.

**Table 11.2. Advantages and disadvantages of destructive treatment**

Advantages	Disadvantages
• Simple and cheap	• The destroyed transformation zone cannot be examined histologically
• Widely available equipment	• True diagnosis uncertain
• Effective, when used expertly	• Not possible to rule out cancer or glandular disease
• No expense of histological examination of the transformation zone	• Concern about depth of excision
	• Margin status not known

**Table 11.3. Conditions for destructive treatment**

Condition
• The TZ must be fully visible (i.e. type 1 or type 2 TZ) and accessible (i.e. type 1 TZ or shallow type 2 TZ).
• The TZ must be small enough to be covered by the destructive method probe.
• Invasive disease must be ruled out.
• There should be no suspicion of glandular disease.
• There should be no disparity between cytology and colposcopy.
• There should not have been a previous treatment of the cervix.
• There should not be upper or lower genital tract infection (relative contraindication).
• The patient should not be pregnant.
• If the patient has recently delivered, she should be at least 3 months postpartum.

TZ, transformation zone.

include laser treatment (Monaghan, 1995), radical diathermy (Chanen and Rome, 1983), and cryosurgery (Hatch et al., 1981). The temperature applied in radical diathermy reached 300 °C; it is no longer used and is of historical interest only. As a destructive technique, laser treatment has few advantages over cryosurgery or thermal coagulation in resource-limited regions and will not be discussed in depth here. The interested reader is referred to excellent descriptive publications (Monaghan, 1995).

This chapter is devoted to two methods of destructive therapy and several excisional methods. The destructive techniques are cryosurgery (also known as cryocautery, cryotherapy, or cryo) and thermal coagulation (also called cold coagulation). The excisional techniques are LLETZ/LEEP and other modifications of electrosurgical excision. Cold-knife conization is also used in some regions and may have a role in excising a type 3 TZ or where there is a suspicion of glandular disease, but otherwise cold-knife excision has little to recommend it. Although hysterectomy is also used as a method of excising CIN, this is nearly always inadvisable. For women with precancerous lesions, hysterectomy offers no advantage over local excision of

the lesion, and for those women in whom unsuspected invasive disease is revealed at hysterectomy, the patient will have been poorly served. After a simple hysterectomy, it is not possible to offer the appropriate radiotherapy regime, and radical hysterectomy is also not possible. Hysterectomy should not be used as a treatment of CIN.

### 11.3.1 Cryotherapy

Cryotherapy, which was popular in the USA during the 1970s and 1980s, was introduced into clinical practice by Crisp et al. (1967) and has been used in many countries for several decades. Cryotherapy is also known as cryocautery, cryosurgery, or cryo. Where the equipment is available and the gas supply is assured and when the preconditions for destructive therapy have been met, it is a reasonable choice of therapy. It has few serious complications, and although it is described as causing relative discomfort, it is usually well tolerated without the need for local infiltration, so that it may be performed as an outpatient procedure or in a rural clinic. The capital equipment necessary is inexpensive, although the price of gas and the cost of transporting

the gas cylinders are quite variable. Cryotherapy gas tanks are large and are heavy (10–15 kg) and thus difficult to transport. They require refilling relatively frequently. At a clinical level, the major disadvantage of cryotherapy, and of all destructive techniques, is the lack of tissue to allow histological examination. Finally, cryotherapy treatment takes considerably longer (approximately 15 minutes from start to finish) than thermal coagulation or LLETZ/LEEP, each of which may be completed in a minute or two, although infiltration of local anaesthetic may add a minute to LLETZ/LEEP. Cryotherapy had become very popular as part of a see-and-treat approach to screening and management in many LMICs in the past decade, but difficulties with maintaining a cheap and reliable supply of carbon dioxide (CO<sub>2</sub>) have limited its popularity.

Cryotherapy achieves a destructive effect by freezing tissue down to less than –20 °C. A metal probe is held in close contact with the TZ epithelium (Figs. 11.1–11.3). Gaseous CO<sub>2</sub> is allowed to escape and circulate *in* the probe head, thereby cooling the cryocautery probe surface that is in contact with the epithelium. The cellular necrosis of the affected epithelial cells occurs as a result of intracellular fluid crystallization and consequent cell membrane rupture. The probe tip must be the appropriate size and shape for the relevant TZ. When the TZ involves the endocervical canal for more than 5 mm (i.e. beyond a shallow type 2

**Fig. 11.1. Cryoprobe tips.**



TZ), it is probably wise not to use a destructive technique. If the method is used for only type 1 TZs and these are small enough to be completely covered by the probe, then success rates are likely to be high. Failure rates are high for lesions that extend to four quadrants of the TZ.

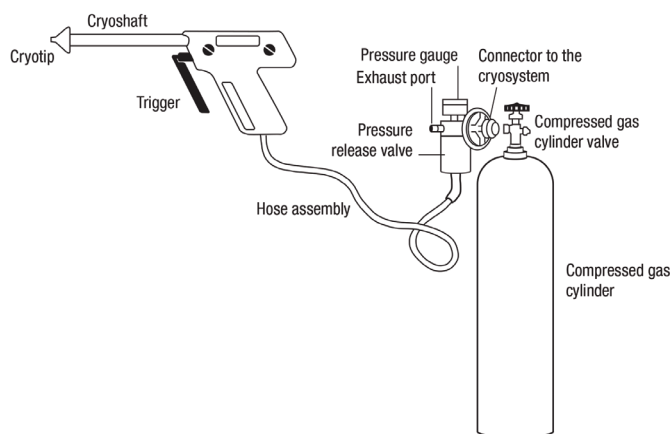
### 11.3.1.1 Equipment for cryotherapy

With the exception of the particular difficulty of gas supply in LMICs, the equipment for cryosurgery is widely available, relatively cheap, and easy to use. A flexible plastic tube connects the handheld cryosurgery device to the liquid gas cylinder. It is important that this tubing is checked for leaks periodically to ensure an adequate and effective supply of gas to the probe. At the cylinder head, the tubing is connected to the cylinder by a tightening knob around a connecting bracket (Fig. 11.2).

After passing through the connecting aperture, the gas travels through a silencer and pressure gauge. In most machines, the gauge will display when pressure is sufficient to provide the necessary temperature drop *throughout* the procedure. Small gas cylinders, although more easily transported, do not contain enough gas for more than a few procedures, and so larger cylinders are better for busy clinic sessions. CO<sub>2</sub> and nitrous oxide (N<sub>2</sub>O) are equally effective cryogenic gases.

When the gas reaches the device, its release is controlled by a trigger. This releases the gas through a small aperture in the cryoprobe; it then circulates within the probe and freezes the probe tip. When applied to the TZ epithelium, the probe tip then effects tissue necrosis. Whether CO<sub>2</sub> or N<sub>2</sub>O is used, the temperature of the tissue for ablation should reach -20 °C throughout. Providing that the gas cylinder maintains sufficient

**Fig. 11.2.** A typical cryosurgical unit attached to a cylinder of either CO<sub>2</sub> or N<sub>2</sub>O.



pressure (> 40 kg/cm<sup>2</sup>), the tissue in contact with the probe will necrose if the probe is held in contact with it. Table 11.4 details the temperature achieved at cryotherapy. When the pressure drops below 40 kg/cm<sup>2</sup>, the gas cylinder should be replaced with a full one.

Details of standards in cryocautery equipment and how to perform the procedure, as well as details of sterilization procedures, are contained in the WHO technical specifications document “Cryosurgical equipment for the treatment of precancerous cervical lesions and prevention of cervical cancer” (WHO, 2012).

### 11.3.1.2 Treatment with cryotherapy

Providing that the conditions for using a destructive method (Table 11.3) have been satisfied, cryosurgery may be performed at the first

assessment visit or after a diagnostic biopsy. The purpose of this manual is not to proscribe patient management, and local circumstances will modify management strategies, but a comprehensive colposcopic examination with or without a directed biopsy (or biopsies) is the gold standard pre-treatment investigation for women who are screen-positive. Financial, equipment, and training constraints may preclude the possibility of providing colposcopy. Successful screen-and-treat protocols have been implemented in many LMICs.

After an adequate colposcopic examination and informed consent, with the patient in the lithotomy position and a speculum in place, the cervix should be perpendicular to the colposcopic line of vision so that the probe may be applied evenly across the TZ. The speculum should be comfortable and large enough to expose the entire cervix and to separate the cervix from adjacent vaginal

**Table 11.4.** Cryocautery equipment temperature, when contact between probe and epithelium is uniformly good and gas pressure is maintained at > 40 kg/cm<sup>2</sup>

Gas used	Temperature at probe tip	Temperature at probe edge	Temperature of central tissue	Temperature at edge of tissue
CO <sub>2</sub>	< -68 °C	-20 °C	-68 °C	About -20 °C
N <sub>2</sub> O	< -89 °C	-20 °C	-89 °C	About -20 °C

walls. A support person, usually a nurse attendant, is invaluable in comforting and reassuring the patient before and during the procedure. The clean, non-pregnant and uninflamed cervix should be free of mucus, and the TZ should be completely accessible to contact with the cryoprobe. This will usually mean a small type 1 TZ or a small and shallow type 2 TZ.

After cleaning, the cryosurgery probe should be firmly applied to the TZ on the cervix and the cryosurgical effect begun by activating the trigger (Fig. 11.3a and b). A stopwatch is useful to time the procedure. The operator should observe the procedure, to ensure adequate contact and to ensure that the vaginal walls are not in contact with the probe during the freeze. The procedure is uncomfortable but is not usually described as painful. A slight hissing noise is emitted from the cryosurgery probe during active freezing. Treatment should be performed in two phases – a 3-minute freeze, followed by a 5-minute thaw, followed by a 3-minute freeze – so as to ensure adequate depth of tissue necrosis ( $\geq 5$  mm). Ideally, a stopwatch should be used; otherwise, a busy clinician may overestimate the passage of time. Technically, it is a simple procedure. Maintaining even but firm contact with the tissue is important at the outset, but once a freeze

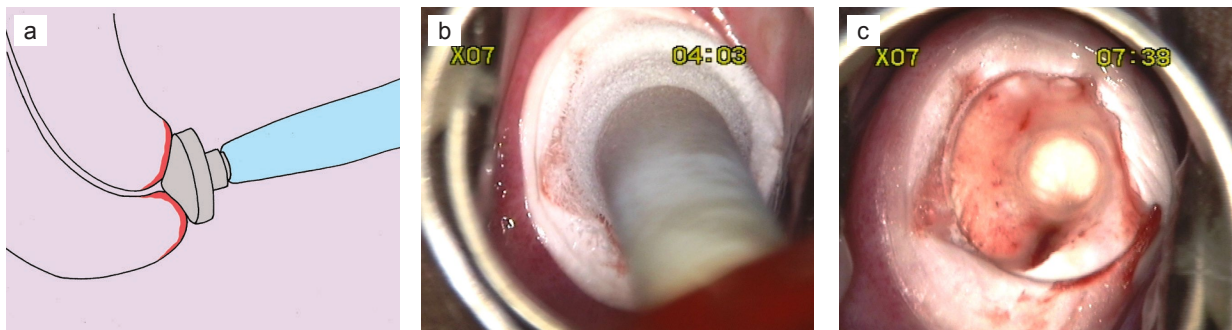
has occurred, the probe does not detach from the tissue. It is important to be careful that the vaginal walls do not fall against the frozen tissue or probe, so as not to cause inadvertent damage. Finally, after each freeze a minute or so should be allowed before detaching the probe, to allow it to easily separate from the tissue. The probe and cryosurgery device should then be thoroughly cleaned (see Chapter 18).

After cryosurgery, the vagina should not be packed. Providing that the cervix was not inflamed, there is no need for antibiotic or other treatment. The patient should be advised not to use internal tampons, not to douche, and not to have penetrative intercourse for at least a month or until all discharge has stopped. A take-home information sheet is valuable. It should detail the follow-up arrangements and briefly describe the usual effects and complications associated with cryosurgery. Healing is usually complete after 6 weeks, and during this time it is common to experience a light watery and slightly bloodstained discharge. Excessive and/or offensive discharge, bleeding, pain, fever, or any suspicion of cervicitis or pelvic inflammatory disease warrants a clinic visit. A checklist for cryosurgery is given in Table 11.5. Finally, the risk of HIV acquisition by HIV-negative women (or

transmission between patients) after cryosurgery is unknown; very limited data are available.

To perform as effectively as possible, the machine needs to be working properly and needs to have a constant supply of CO<sub>2</sub>, and the operator should use the double-freeze technique. Results in the literature are somewhat variable. In the early non-controlled studies, the success of cryocautery for CIN3 varied between 77% and 93% (Benedet et al., 1981; Hatch et al., 1981; Popkin et al., 1978). The Cochrane meta-analysis review of 29 trials covering 4509 cases, 1843 of whom had CIN3, found a lower rate of treatment success for CIN3 for cryotherapy compared with thermal coagulation (Martin-Hirsch et al., 2013). The single-freeze cryotherapy technique was associated with a non-significant increase (relative risk, 2.66; 95% confidence interval, 0.96–7.37) in the risk of residual disease compared with the double-freeze technique (Schantz and Thormann, 1984). The authors of the Cochrane review concluded that there was no overwhelmingly superior surgical technique for eradicating CIN and that cryotherapy appeared to be an effective treatment of low-grade disease **but not of high-grade disease**. This conclusion concurs with recent results of non-comparative

**Fig. 11.3.** (a) The cryoprobe in place during treatment. (b) The activated cryoprobe on the cervical transformation zone. Note that the frozen epithelium extends a few millimetres beyond the edge of the cryoprobe. (c) The cervical wound immediately after cryosurgery.



**Table 11.5. Cryosurgery procedure**

Steps/checklist
• Colposcopic examination with or without a biopsy (or biopsies)
• Confirmation of suitability (see Table 11.3)
• Counselling and informed consent
• Check equipment status (probe clean, pressure > 40 kg/cm <sup>2</sup> , no leaks)
• Speculum insertion, lithotomy position
• Procedure room door locked, nurse attendant present, patient relaxed
• Probe applied to transformation zone on the cervix
• Contact with epithelium good
• Gas release trigger activated, stopwatch started
• Freeze observed, vaginal walls not in contact with probe or any frozen tissue
• Freeze maintained for 3 minutes
• Thaw allowed for 5 minutes
• Second freeze maintained for 3 minutes
• Remove probe after thawing

observational studies. For example, in the study of Nene et al. (2008) of cryotherapy performed by midwives in India, the cure rate of CIN3 was 82.1% (95% confidence interval, 74.7–89.4%) for CIN2 and CIN3 lesions combined. These relatively low rates of cure may be unacceptable in some regions. However, WHO has stated that where resources are limited, cryosurgery, as part of a screen-and-treat programme, is an acceptable option to treat high-grade lesions also.

### 11.3.2 Thermal coagulation

The term “cold coagulation” is a misnomer, and the method should properly be called thermal coagulation. The probe is heated electrically and reaches temperatures of 100–120 °C (Duncan, 1983). The technique was named cold coagulation to discriminate it from radical diathermy, which reaches temperatures of 300 °C. The method was introduced to clinical practice by Kurt Semm (Semm, 1966) in Kiel, Germany, and was used widely throughout Europe in the 1970s and 1980s. Much of the

published work on cold coagulation came from the United Kingdom, in particular from Ian Duncan’s unit in Dundee (Duncan, 1983, 1984; Gordon and Duncan, 1991). The method was not widely used in North America, where cryocautery and then laser ablation were the destructive method of choice. With thermal coagulation, the intracellular water reaches boiling point and the cells necrose. It achieves tissue destruction to a depth of 4–7 mm (Haddad et al., 1988). The method fell out of popularity (Semple et al., 1999) when LLETZ/LEEP was introduced but is now being reconsidered, because of its apparent advantages over cryocautery and because excisional techniques are not considered feasible in remote regions by relatively untrained staff in poorly equipped facilities without the necessary additional resources (e.g. histopathology services and the very occasional need for general anaesthesia). Thermal coagulation has equivalent success rates to cryosurgery, is quicker to perform with similarly low complication rates, and does not require refrigerated gas. The procedure takes

less than 2 minutes to complete and is usually performed without either general or local anaesthesia; it appears to be well tolerated. Finally, although the energy is produced electrically, newer thermal coagulation units are battery-operated and can provide sufficient battery power for 30 procedures before recharging is necessary.

#### 11.3.2.1 Equipment for thermal coagulation

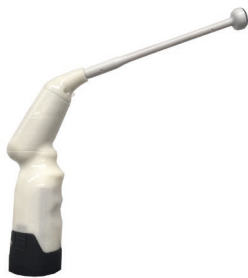In the early papers reporting the use of thermal coagulation, Gordon and Duncan wrote that the Semm coagulator was very user-friendly, because it was quick and silent and did not require local or other analgesia. In their original series, 95% of patients required no anaesthesia. The capital equipment is relatively inexpensive (equivalent to costs for cryosurgery) and easily portable. The therapeutic temperature is 100 °C, which is not high enough to produce charring or smoke, thereby avoiding any unpleasant odour for the patient and doctor. Neither a suction machine nor a filter is required, because there is no smoke plume. All the equipment is reusable. There are enough probes of different dimensions to accommodate almost all type 1 TZs, and postoperative discharge and bleeding were not reported to be a problem for most women.

Subsequent pregnancy and fertility rates do not appear to be affected by thermal coagulation. Also, it may be applied as one or several applications for large or irregular ectocervical TZs. Finally, at the time (in the 1970s and 1980s), it was rightly seen as an inexpensive alternative to the then-popular laser ablation technique. Its singular disadvantage is that the TZ epithelium is destroyed rather than preserved, thereby negating the opportunity for histopathological examination.

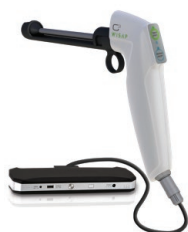### 11.3.2.2 Treatment with thermal coagulation

Treating the TZ using the thermal coagulator could not be simpler. Several manufacturers produce thermal coagulators (Figs. 11.4 and 11.5). Each produces clear instructions about when the temperature of 100 °C has been reached and when it has returned to normal body temperature. Applying the probe is exactly the same as applying a cryoprobe, except that there is no visible ice ridge just outside the probe during activation and, unlike electrosurgical techniques (LLETZ/LEEP, etc.), there is no smoke plume to evacuate. As with any destructive or excisional technique, it is entirely possible to damage the epithelium and other adjacent structures if the probe is applied to anywhere other than the cervix, but it is difficult to do this, providing that the vaginal walls are clearly seen to be distant to the cervix and the thermal coagulation probe head. A checklist for thermal coagulation is given in Table 11.6.

**Fig. 11.4.** The Liger thermal coagulator.



**Fig. 11.5.** The WISAP “cold” coagulator.



**Table 11.6.** Thermal coagulation procedure

Steps/checklist
• Colposcopic examination with or without a biopsy (or biopsies)
• Confirmation of suitability (see Table 11.3)
• Counselling and informed consent
• Check equipment status (probe clean, temperature gauge functional)
• Speculum insertion, lithotomy position
• Procedure room door locked, nurse attendant present, patient relaxed
• Probe applied to transformation zone on the cervix
• Contact with epithelium good
• Vaginal walls not in contact with probe or any frozen tissue
• Thermal coagulation probe activated, stopwatch started
• Temperature > 100 °C maintained for 45 seconds
• If transformation zone larger than thermal coagulation probe head, apply probe for further 45 seconds to untreated area, overlapping with the previous treatment
• Remove probe

## 11.4 Excisional methods

There are several ways of removing the TZ. These include hysterectomy, cold-knife excision (also known as cold-knife cone biopsy or cold-knife conization), laser cone biopsy, LLETZ/LEEP, and other variations of electrosurgical excision, for example SWETZ, which is an alternative to LLETZ/LEEP, laser excision, or cold-knife excision when performing a type 3 excision (Camargo et al., 2015).

### 11.4.1 Hysterectomy

Hysterectomy has been very widely used to treat suspected or proven cervical precancer. The advantage of ridding a woman of fertility and menstruation and any associated symptoms as well as treating separate benign pathology (e.g. fibroids or adenomyosis) may seem attractive in the presence of CIN. However, the risk of undertreatment of unsuspected invasive disease means that an adequate and satisfactory colposcopic examination should be performed before hysterectomy for CIN. If invasive disease is discovered at

hysterectomy, the woman will have been undertreated and it will no longer be possible to offer the optimal radical hysterectomy or radiotherapy regime. In the great majority of cases, it is far more sensible to resect the TZ first and deal with associated pathology subsequently.

### 11.4.2 Cold-knife cone biopsy

Cold-knife cone biopsy, the oldest method of local excision, is still widely used, especially where colposcopy facilities and/or expertise are not available. It has similar success rates to other excisional techniques (Larsson, 1983). The technique leaves a relatively large cervical defect and will often remove more tissue than is necessary. The procedure is usually performed under general anaesthesia. A suture or sutures are often used to achieve post-excision haemostasis. Cold-knife cone biopsy is associated with well-recognized short- and long-term complications, including primary and secondary haemorrhage, cervical stenosis, and cervical incompetence. It may be worth considering with a type 3

excision for glandular or microinvasive disease, but otherwise cold-knife excision has no advantage over LLETZ/LEEP or laser excision and is associated with greater morbidity and long-term pregnancy-related complications than the other excisional techniques (Arbyn et al., 2008; Jones et al., 1979; Kristensen et al., 1993).

### 11.4.3 Large loop excision of the transformation zone (LLETZ/LEEP)

LLETZ is the term coined in the early 1980s to describe excision of the TZ using a low-voltage diathermy loop of thin wire usually with blended diathermy under local anaesthesia. The term was coined to discriminate it from the small loops that René Cartier used for taking biopsies in his practice in Paris, and it is from his technique that LLETZ (and LEEP) was developed. It was developed in Bristol, United Kingdom, in the early 1980s (Prendiville et al., 1986, 1989). LEEP is a term that was introduced after the introduction of LLETZ to the USA and was purportedly coined to describe loop electrosurgical excisions of the TZ and for other lower genital tract lesions. In truth, LEEP is identical to LLETZ.

## 11.5 Electrosurgery for CIN

A simple glossary of terms is given in Table 11.7.

### 11.5.1 Principles of electrosurgery

Electrosurgery has been used for more than a century to both cut and coagulate tissue. Heat has been used for centuries to coagulate bleeding wounds and vessels. The heat was originally transmitted using a metal implement heated in a fire. For the past century, electrical generation

**Table 11.7.** Glossary of terms related to electrosurgery for CIN

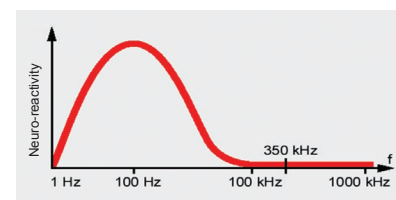
Term	Explanation
Ampere	The unit of measurement of electric current; the amount of electricity passing along a circuit (the number of electrons per second passing through a circuit).
Cautery	Heating tissue to produce coagulation.
Coagulation diathermy	Electrosurgical effect achieved by interrupted passage of high-frequency electricity, whereby cells are exploded at temperatures < 100 °C, typically about 70 °C.
Cutting diathermy	Electrosurgical effect achieved by constant passage of high-frequency electricity, whereby cells are exploded at temperatures > 100 °C.
Diathermy	Stimulation of tissue with electrically induced heat. The diathermy effect may be coagulative or cutting and occurs at the point of contact.
Electrosurgery	Electrical stimulation of tissue. The effect may be coagulative or cutting and occurs at the point of contact.
Ohm	The unit of measurement of electrical resistance of tissue.
Volt	The unit of measurement of electromotive force, which is required to send electrons through a circuit.

has been used as a controlled way of providing localized heat to coagulate tissue and blood vessels. The passage of electricity to and through tissue produces heat. The discovery by Faraday that muscle does not contract when contacted by alternating current of very high frequency (> 100 000 Hz, i.e. > 100 kHz) means that it is possible to perform safe passage of electricity through controlled circuits in the human body and to use the localized point-of-contact effect to achieve cutting or coagulation, or a combination (blend) of the two. Electrosurgical energy operates at frequencies of more than 300 kHz, when contraction of muscle is overcome (Fig. 11.6).

Monopolar diathermy or electrosurgery is used during LLETZ, whereby electrical current passes from the ESU through the electrode (here, a loop) to the tissue and thence through the body to the return electrode (ground plate) and ultimately back to the ESU. Since the electrical energy is concentrated into a very small area (here, the loop wire), the electrosurgical effect will be achieved at the point of contact, i.e. as the wire

approaches and passes through the tissue. For most electrosurgical machines, a blend of cutting and coagulation achieves the desired effect of cutting through tissue and achieving relative haemostasis of the stromal vessels, without inflicting significant diathermy artefactual damage on either the biopsy specimen being removed or the cervical stromal wound left behind. Output and waveforms vary between ESUs, but a blend of about 20% coagulation and 80% cutting is usually optimal. The loops themselves (i.e. the active electrode) are usually made of stainless steel or tungsten wire (Fig. 5.16). The technique is simple and easy to learn, but it is best learned using ox tongue or

**Fig. 11.6.** Electrosurgical energy operates at frequencies of more than 300 kHz, when contraction of muscle is overcome (the Faraday effect).





some other meat or simulated tissue (e.g. playdough). The method is illustrated diagrammatically in Figs. 11.7 and 11.8.

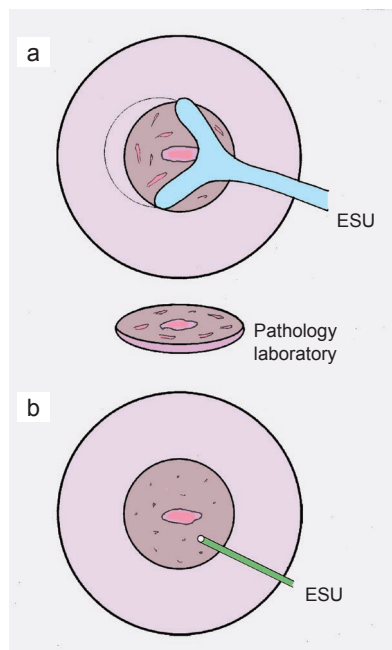
### 11.5.2 Electrosurgical effects: fulguration versus desiccation

When passing the activated electrode through the tissue or when achieving coagulative diathermy to effect haemostasis of the LLETZ wound, it is important to try to produce a fulgurative rather than a desiccative electrosurgical effect. With fulguration, the electricity passes across a very small air gap to the tissue at relatively high temperatures. This will usually achieve very superficial tissue damage and a sufficient cutting or coagulative effect for LLETZ. With desiccation, there is full contact between the electrode and

the tissue, and the electrosurgery produces a lower temperature but a deeper diathermy effect. It is less coagulative and more damaging in its effect. Desiccation is appropriate in diathermy ablation of the endometrium, for example, but undesirable when cutting through or coagulating the post-LLETZ wound. In practice, one can achieve a fulgurative rather than a desiccative effect by:

- activating the electrode (i.e. the loop) before contacting the tissue;
- passing the loop slowly through the tissue, whereby a small steam window will occur between the loop and the tissue; in this way, the loop will not bend as it passes through the tissue underneath and around the TZ (Fig. 11.8); and
- holding the ball diathermy electrode just off the tissue when attempting haemostasis, and producing a visible spray of electricity between the ball and the tissue (Fig. 11.7b).

**Fig. 11.7.** Diagrammatic representation of (a) the LLETZ technique and (b) post-LLETZ ball diathermy management of the wound (ground plate not shown). ESU, electrosurgical unit.



## 11.6 Safety issues with LLETZ

### 11.6.1 Ground-plate contact

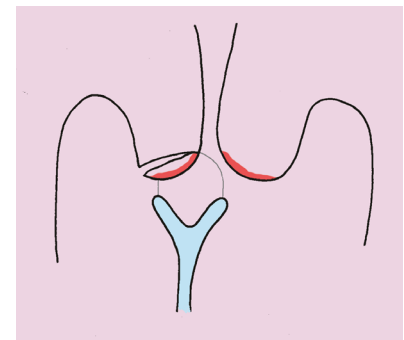
LLETZ uses monopolar electrosurgery and therefore needs a ground plate for the electricity to return to the ESU after achieving its effect at the point of contact between the loop and the tissue (or the ball electrode and the post-LLETZ wound). If there is poor ground-plate contact, an injury can occur when the current finds an easier pathway to return to ground. Examples of sites are the metal stirrups of some gynaecological couches, jewellery, or other metal body adornments. Metal jewellery and adornments should, of course, be removed before any electrosurgery, but they are unlikely to cause injury if the ground plate is large and in good contact with the skin, especially if the ESU has a resistance recognition system and uses a split ground plate.

To prevent passage of electricity to somewhere other than the ground plate, it should be positioned relatively close to the point of contact. For LLETZ, a convenient and appropriate position is under the patient's buttocks. Having the patient's buttocks on the ground plate will help ensure complete contact, which reduces the risk of burn injury. The ground plate (return electrode or dispersive pad) is wide, and this together with good contact of skin to the entire plate will prevent focal contact and a burn. Many recently manufactured ESUs incorporate a resistance recognition system in the ground-plate circuitry such that electricity will be cut off if there is not good contact. Typically, these ground plates are split, and an even flow through both is necessary to allow electricity to pass around the circuit. Often, an alarm warns the operator if there is not good ground-plate contact.

### 11.6.2 Prevention of electrosurgical injuries

It is possible to injure the vaginal wall and the structures immediately adjacent to it. Electrosurgical injuries to

**Fig. 11.8.** The loop should be passed slowly through the cervix underneath the transformation zone, so slowly that the loop wire does not bend. If it does, the operator is pushing it too quickly through the tissue, and the electrosurgical effect changes from fulgurative to desiccative.



the bladder, urethra, and bowel have been reported. The loop electrode has no respect for tissue planes. Care while introducing the electrode through the vagina and while removing it is fundamental to all vaginal surgery. Complete visualization of the electrode during activation is mandatory. Finally, the cervix and the entire loop should be seen under colposcopic visualization before, during, and after the LLETZ procedure. To ensure complete visualization, the operator has to switch the magnification control to the *lowest* magnification setting (about 4×) before starting the LLETZ procedure. Activating the electrode without being able to see all of it and the entire cervix is dangerous.

If the vagina is touched by the loop or ball electrode, it may cause a superficial or deep injury, and injury to deeper organs may not become apparent until some days after the procedure. It is very difficult to defend a direct electrosurgical injury to the vaginal wall or an adjacent organ.

It is nearly always possible to keep the vaginal walls distant from the cervical TZ by using an appropriately sized speculum. If the walls are particularly patulous, a condom (with its end cut off) placed around the speculum (Fig. 5.11b) is usually effective; if this does not work, ancillary speculum blades or lateral wall retractors will do, but they are rarely necessary.

### 11.6.3 Speculum insulation

Some authorities have advocated the use of insulated specula when using electrosurgery, in the belief that this will reduce the risk of accidental electrosurgical injury due to contact of the loop or ball electrode with the speculum. This is unwise. Insulated specula lose their insulation over time, particularly if autoclaved. Tiny holes will occur, which are not

often visible to the naked eye; if any insulation-free area of the speculum has contact with the electrode, these holes are so small as to create a high current density on the return to the ESU, whereby an injury is *more* likely to occur. If an uninsulated speculum is accidentally contacted by a loop or ball electrode, the surface area of the speculum is so large that a burn is unlikely. In other words, hitting an uninsulated speculum with the activated electrode is less likely to cause injury than touching a poorly insulated speculum with the electrode.

### 11.6.4 Other avoidable injuries

To avoid injuries due to alcohol-containing fluids, it is fundamental that no explosive or inflammable fluids are used in the vicinity of electrosurgical procedures.

Accidents may occur during the learning curve of LLETZ. A woman expects, rightly, that the colposcopist will be skilled in LLETZ before approaching a patient. It is relatively easy to become competent at LLETZ before one's first procedure on a patient, by learning and performing the technique using ox tongue or other meat samples or on a simulator, under supervision and repeatedly. Common sense means that this should be routinely practised as part of any training scheme.

### 11.7 A practical approach to the LLETZ procedure

After clear, adequate counselling and informed consent, ask the patient to lie on a gynaecological couch in the lithotomy position (see Chapter 5). With all the necessary equipment to hand and with an attendant present, introduce an appropriately sized suction speculum and expose the cervix. Adjust the speculum so that the cervix is perpendicular to the

colposcopic line of vision. Examine the cervix and TZ as described, and after confirming the indication for treatment, begin the procedure.

It should start with adequate infiltration of local anaesthetic. A variety of methods for local infiltration have been described. A popular technique is to use a dental syringe to infiltrate either prilocaine with felypressin or lignocaine with adrenaline subepithelially. The dental syringe has the advantage of having fewer side-effects and a much reduced risk of vasovagal attack. Local anaesthesia in this procedure is not attempting a regional block, and the aim is to infiltrate everywhere that the loop will pass. If using prilocaine with felypressin, infiltrate 2–4 vials (2.2 mL in each) for a medium-sized TZ. It is possible to use less, but side-effects with this preparation are exceedingly rare and using this much will ensure adequate anaesthesia; indeed, this is usually a totally pain-free procedure. Using sufficient infiltration also reduces the amount of peri- and post-LLETZ bleeding, so that haemostasis is more easily achieved. Some bleeding does occur from the infiltration needle puncture sites but is rarely problematic.

After infiltration of local anaesthetic, attach the diathermy ground plate from the ESU port to the patient, and attach the suction tubing to the suction tube on the underside of the anterior blade of the speculum and activate the suction. At this stage, the colposcope should be set to low magnification so that the entire loop, cervix, and vaginal walls may be seen. Set the appropriate power setting on the ESU. Next, the *unactivated* loop should be introduced and held only a millimetre or so off the entry point for resection under direct binocular colposcopic view. The loop electrode should be activated just before making cutting contact with the epithelium. A blend of

coagulation and cutting may be used (i.e. blend 1, or 20% coagulation and 80% cutting) so as to minimize the coagulating diathermy effect on the extirpated TZ and the LLETZ wound. The entry point should usually be only a millimetre or two outside the outer limit of the TZ.

It is preferable to resect the TZ, usually in one piece from the 9 o'clock position, thereby passing from the patient's right to left. In this way, the resected TZ does not fall onto the loop, as can happen when resecting antero-posteriorly. While performing the procedure, the colposcopist should be conscious of the depth of the loop in the stroma underneath the TZ epithelium. Fig. 11.9 presents a simple LLETZ in a type 1 TZ, i.e. a type 1 TZ excision.

After the TZ is removed, it should be transferred to the attendant, who may transect it and pin it onto a cork board before immersion in formalin (Fig. 11.10). It is also worth immersing the extirpated TZ in a graduated

cylinder of fluid to assess volume. Volume of excision appears to be a reliable prognosticator for future pregnancy-related complications (Castanon et al., 2014; Khalid et al., 2012; Kyrgiou et al., 2014).

The aim of treatment by LLETZ is to excise the entire TZ and only the TZ to a depth of about 5–7 mm. This is sufficient to resect virtually all epithelial crypts, and the diathermy artefactual damage of the loop will inflict artefactual diathermy necrosis for a further 2–3 mm. Although it might seem sufficient to resect only the lesion within the TZ, the published treatment success rates relate to treatment by excising or destroying the entire TZ and not only the lesion.

### 11.8 Post-LLETZ wound management

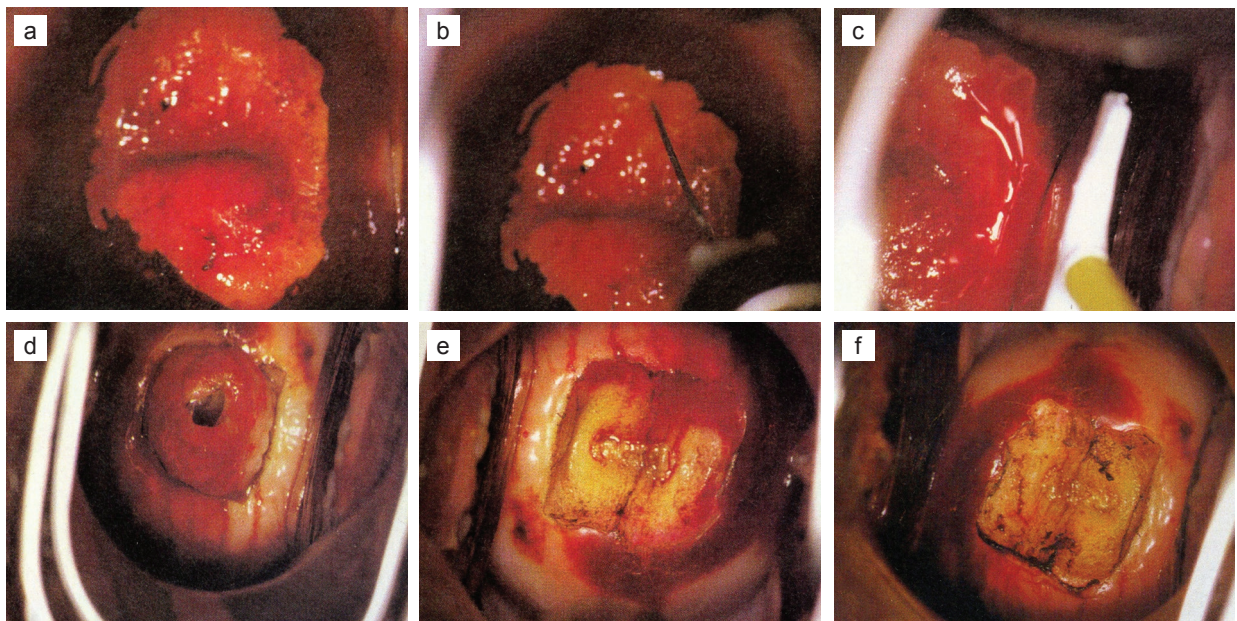
There are few RCTs of post-LLETZ management, but the evidence suggests that Monsel's paste (see

Annex 5), on its own or after initial ball electrode *point diathermy* of any bleeding points, is highly effective and minimally damaging to the LLETZ wound bed. If using diathermy to achieve coagulative haemostasis, use a small ball and a fulgurative technique. Try to ensure that the upper limit of resection (the new SCJ) is *not* diathermized, to reduce the risk of functional stenosis (Paraskevaidis et al., 2001a). Finally, any blood or iodine may be evacuated from the posterior vaginal fornix with a large cotton swab, and the speculum then removed. While the patient is dressing, the procedure should be documented. Thereafter, the patient may be counselled about the procedure and the follow-up arrangements.

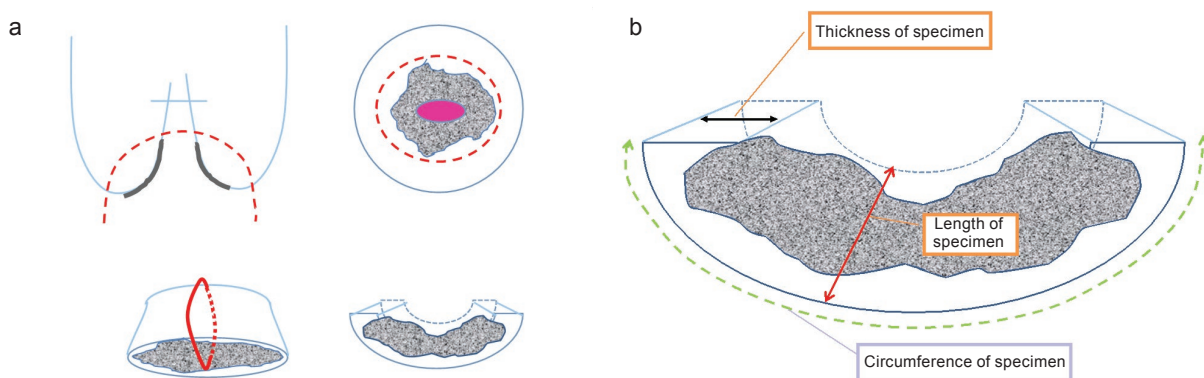
### 11.9 Management of the specimen

The extirpated TZ will be processed according to the preferences of the pathologist. Some prefer to section

**Fig. 11.9.** A simple type 1 excision in a patient with HSIL in a type 1 transformation zone. (a) The cervix after the application of Lugol's iodine. (b) Local infiltration of prilocaine with felypressin. (c) The loop just before the procedure. (d) The cervix immediately after the procedure, with the resected transformation zone still in situ. (e) The cervical wound before fulgurative diathermy coagulation. (f) The cervical wound after fulgurative diathermy coagulation.



**Fig. 11.10.** A type 1 transformation zone that has been removed at LLETZ and opened. (a) A simple LLETZ; after resection, the removed transformation zone is opened and pinned onto a cork board before immersion in formalin. (b) The dimensions of the opened specimen.



the unopened disc of tissue, and others to open it before fixing in formaldehyde. The latter technique has the advantage that it allows for longitudinal sections through the entire length of the excised TZ and allows assessment of margin status at either end of the specimen (i.e. endocervical and ectocervical margins). Because of the confusion in the literature between terms like “depth” and “height”, these terms have been abandoned in the latest IFCPC nomenclature, and instead the more universally understood terms “length” and “thickness” (of the open specimen) have been included. These dimensions are illustrated in Fig. 11.10 (see also Fig. 7.9).

### 11.10 Post-treatment advice to patients

Every patient should be given a clearly written handout of post-LLETZ instructions, and these should be explained verbally before the patient leaves the clinic. The handout should state what has been performed, describe the likely short-term course (mild bleeding for a few weeks), provide advice to abstain from penetrative intercourse for a month, and state what follow-up arrangements have been made. The patient should be advised to return to the clinic if

there are symptoms suggestive of either a severe infection or, more seriously, an electrosurgical injury.

### 11.11 Complications after LLETZ

In the short term, complications after LLETZ are mild but are to be expected. These include light per vaginal bleeding, mild discomfort, and a little discharge. The bleeding during the first 2 or 3 weeks is not usually more than that which occurs during normal menstruation, providing that the cervix was not inflamed at the time of LLETZ. Severe bleeding or symptoms suggestive of a secondary infection (bleeding greater than during normal menses, discharge, and/or pain) are uncommon and should precipitate immediate return to the clinic service.

It is entirely biologically plausible that excision of part of a reproductive organ is likely to compromise its function. Since the review of Kyrgiou et al. (2006), there have been a plethora of publications reporting conflicting evidence about the risk of premature labour after excisional treatment for cervical precancer. The most recent review of the evidence suggests that removing a small type 1 TZ is associated with an

insignificant increase in subsequent pregnancy-related complications, whereas removing a large amount of tissue by cold-knife excision, laser excision, or electrosurgery is likely to cause a definite increase in subsequent pregnancy-related complications (Arbyn et al., 2008; Castanon et al., 2014; Khalid et al., 2012; Kyrgiou et al., 2006, 2014; Strander and Adolfsson, 2014).

### 11.12 See-and-treat

“See-and-treat” has several interpretations. It may mean that:

- every patient with an abnormal smear report who has been referred for colposcopy is treated at their first visit in the colposcopy clinic (non-selective see-and-treat); or
- every woman who has a positive screening test (e.g. VIA) is treated at the time of the screening test (non-selective screen-and-treat); or
- only those women in whom both the primary screening test and the colposcopic impression are in agreement and suspect a high-grade abnormality are treated (selective see-and-treat).

Non-selective see-and-treat (i.e. screen-and-treat) protocols will treat a large proportion of patients who

would not have developed cancer. This is not to say that this policy is wrong; it may be the most efficient and effective way of reducing cancer rates in a particular region. But where competently performed colposcopic examination is available, it is better to select for treatment only those who have a high risk of progression and to monitor those who have a low risk of progression. There is now good evidence that the risk of progression to cancer for histologically proven CIN1 is similar to the risk for normal epithelium.

The logic supporting a selective see-and-treat protocol is that for women with a clinically significant risk of progression to cancer (i.e. HSIL suspected cytologically and also at colposcopic examination) or when there is an obvious need to treat, there is little advantage to taking a biopsy and asking the patient to return when the result is available. During one calendar year at the Coombe Women & Infants University Hospital in Dublin, Ireland, where a selective see-and-treat protocol prevailed, histological audit revealed a very low rate of negative histology in the extirpated TZs (< 1%). There were, however, a relatively large number of low-grade lesions (13.0%, or 30 of 230 cases) revealed at histology. On closer examination of the case records of these patients, the majority (19 of 30) were older than 40 years and had completed their family. The remainder had a referral smear that suspected ASCUS-H (ASCUS, cannot exclude HSIL) or CIN2 (6 cases), ASCUS (4 cases), or atypical glandular cells of undetermined significance (AGUS) (1 case). The United Kingdom clinical guidelines document expects that a see-and-treat protocol should not produce negative or low-grade histological reports in more than 10% of cases (NHS, 2016). However, in women older than 40 years who

have completed their family, it is reasonable to treat at a lower threshold than HSIL. A selective see-and-treat protocol is very patient-friendly and is a very efficient use of limited resources.

### 11.13 Modifications of LLETZ technique: SWETZ; type 2 and type 3 excisions

The LLETZ (or LEEP) technique described above is for a type 1 excision and is appropriate for the great majority of women with CIN, i.e. for a small or medium-sized type 1 TZ, which will be resectable as an outpatient procedure using local anaesthesia with a small or medium-sized loop (Fig. 11.8). However, for some cases the technique needs to be modified, and some cases require general anaesthesia, most commonly for a type 3 TZ excision. Two examples of different excisional methods follow.

#### 11.13.1 Excision of a large and/or irregular TZ

Optimal excisional treatment is a balance between removing the entire TZ and not removing unnecessary amounts of normal tissue. When the ectocervical component of the TZ (of any type, 1, 2, or 3) is very large or very irregular, it is possible that trying to remove it in one piece may remove a lot of normal tissue. In this case, it is worth considering removing the central part (always including the SCJ). It is then easy to remove or destroy the remaining peripheral TZ parts separately, as depicted in Fig. 11.11.

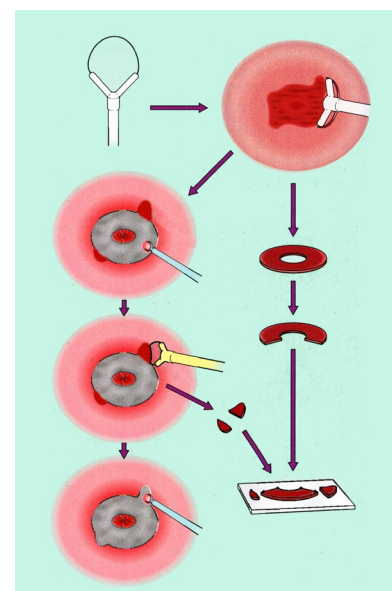
#### 11.13.2 Type 3 excision

Excision types are illustrated in Fig. 7.4. Although type 3 excisions, especially large ones, are known to be associated with an increase in the

risk of subsequent pregnancy-related complications (primarily premature labour) (Khalid et al., 2012), it is sometimes necessary to perform a type 3 excision. Examples include a type 3 TZ with suspected HSIL, glandular disease, or even suspected microinvasion. Performing a type 3 excision is not as simple as performing a type 1 excision and may require general anaesthesia, depending on how large and how long the excision needs to be, access to the cervix, and patient compliance.

Sometimes a large, long loop will be perfectly adequate (Fig. 11.12). However, some colposcopists feel that the risk of inadequate excision margin status at the upper limit is greater with a loop and that a straight wire, laser excision, or even cold-knife excision under general anaesthesia is better. Camargo et al. (2015) have recently published

**Fig. 11.11.** LLETZ removal of the central portion of a large transformation zone (TZ) with the medium loop (20 × 15 mm) in one sweep including the squamocolumnar junction, followed by removal of the peripheral parts of the TZ separately as one or more pieces with one or more passes of the medium or small loop.



a comparison of SWETZ versus LLETZ for the type 3 excision, and they found that SWETZ and LLETZ were equally effective for the treatment of endocervical disease, with no difference in margin involvement. Higher, but not severe, blood loss and longer surgical time were recorded for SWETZ procedures. Fig. 11.13 illustrates the SWETZ technique. Finally, some colposcopists prefer to remove the type 3 TZ by way of the top-hat technique, whereby the TZ is removed in two pieces. After the initial pass removes the ectocervical component, a second, smaller loop removes the upper part of the endocervical TZ (Fig. 11.14; see also Fig. 7.8). However, this technique inevitably inflicts more diathermy damage on the specimen margins.

#### 11.14 Comparison of treatment success rates between LLETZ, thermal coagulation, and cryocautery

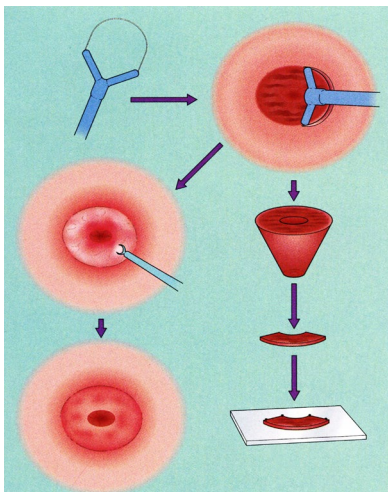
Theoretically, one would not expect there to be a large difference between the methods of treating type 1

TZs. It does not matter whether the TZ is boiled, frozen, or removed; so long as it has been ablated, the precancerous tissue will no longer be present. It is clear that an excisional technique will have certain advantages because of the ability to examine the resected tissue histologically, but providing that cancer and glandular disease were not present and that the TZ was indeed a type 1 TZ, residual disease rates should be similar. Any difference in success rates might reasonably be attributed to the operator rather than the technique.

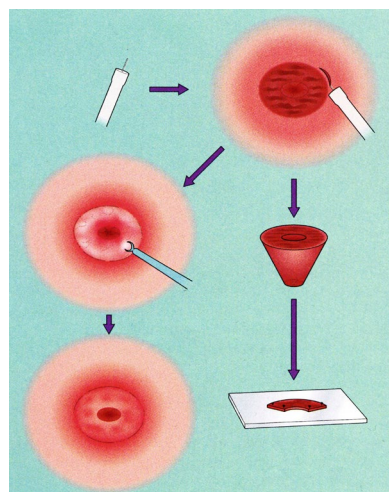
In fact, the published success rates are very similar, with the possible exception of cryosurgery for CIN3. Among excisional methods, cure rates of CIN confirmed by biopsy reached 90–94% with cold-knife cone biopsy, 91–98% with LLETZ, and 93–96% with laser conization. Among ablative techniques, cure rates reached 85–94% with cryotherapy and 95–96% with laser ablation. In terms of side-effects, thermal coagulation appears to be superior to cryocautery; watery discharge persists for the majority of patients (93%) after cryocautery and for relatively

few (17%) after thermal coagulation (Fergusson and Craft, 1974). The interested reader is referred to the meta-analytical reviews of cryosurgery (Sauvaget et al., 2013), of cold coagulation (Dolman et al., 2014), and of all treatments for CIN (Martin-Hirsch et al., 2013). In the Cochrane meta-analysis by Martin-Hirsch et al. (2013), the authors concluded: “The evidence from the 29 RCTs identified [in this meta-analysis] suggests that there is no overwhelmingly superior surgical technique for eradicating CIN. Cryotherapy appears to be an effective treatment of low-grade disease but not of high-grade disease. Choice of treatment of ectocervical situated lesions [type 1 TZs] must therefore be based on cost, morbidity, and whether excisional treatments provide more reliable biopsy specimens for assessment of disease compared to colposcopic directed specimens taken before ablative therapy. Colposcopic directed biopsies have been shown to underdiagnose microinvasive disease

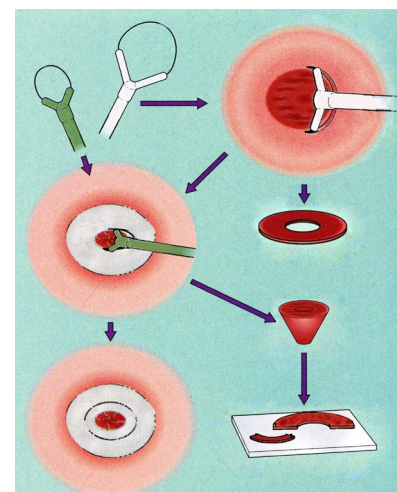
**Fig. 11.12.** LLETZ excision of an entirely endocervical, but fully visible, transformation zone as one piece with one sweep of a large (blue) loop (20 × 20 mm).



**Fig. 11.13.** SWETZ excision of a fully visible and endocervical transformation zone as a cone biopsy using a 1 cm long straight wire as a knife.



**Fig. 11.14.** LLETZ excision of an entirely endocervical, but fully visible, transformation zone using first the medium (white) loop (20 × 12 mm), with subsequent excision of the remaining endocervical part using a small or medium (green) loop (15 × 12 mm).



compared with excisional biopsies performed by knife or loop excision, particularly if high-grade disease is present (Anderson, 1986; Chappatte et al., 1991).”

The available data are not definitive, and often the early observational trials of a treatment are published from centres of excellence. Their experience may not equate to success rates in normal practice. But in summary, from the available data and the practicality issues mentioned above, thermal coagulation would appear to be the treatment of choice where colposcopy and histopathology services are sparse or unavailable. Where they are available, colposcopy and LLETZ are still the gold standard for investigation and management of women with suspected CIN.

### 11.15 Follow-up after treatment of CIN

Because treatment methods are not associated with a 100% success rate, it is important to establish a follow-up protocol to identify the small percentage (< 10%) of those treated who will have residual CIN. The rates of residual disease vary considerably in the published literature,

but some things are well established. First, women who have been treated for cervical precancer are much more likely to develop cervical cancer. This increased risk has been quantified as being 2–5 times the background risk, and much of it is a result of poor long-term follow-up (Soutter et al., 1997; Strander et al., 2007). Several case series of cancer demonstrated that more than 50% of cancers are in women who are lost to follow-up (Ghaem-Maghani et al., 2007) and that this increase in risk lasts for 20 years or more. Excisional treatments permit histological assessment of a biopsy and can determine specific risk factors for residual disease. The NHS Cervical Screening Programme clinical guidelines document details several retrospective studies (Dobbs et al., 2000; Flannelly et al., 2001; NHS, 2010; Schantz and Thormann, 1984) that report residual disease rates after excision and have demonstrated that negative excision margins are associated with lower risk of residual disease and positive excision margins are associated with higher risk of residual disease. Also, those studies that compared endocervical with ectocervical margin status have

demonstrated that disease at the endocervical resection margin is associated with increased risk of residual disease compared with involved ectocervical margins. Women aged 50 years or older are particularly at risk of persistent/recurrent disease (Flannelly et al., 2001; Ghaem-Maghani et al., 2007).

As a result of these studies, it is clear that women need follow-up after treatment. Regional facilities and the cost of colposcopy, cytology, and HPV testing will dictate the appropriate follow-up strategies, but in terms of test characteristics, there is no doubt that HPV testing is the most sensitive test and that it has the best negative predictive values. Several meta-analytical reviews have attested to this (Arbyn et al., 2005). In the context of an organized, systematic call-and-recall screening programme, HPV testing has also been shown to be cost-effective (Coupé et al., 2007), but the cost of HPV testing varies and may not be perceived as being affordable in some LMICs. No matter which method of follow-up is arranged, it should continue for at least 20 years.

## Key points

- Where possible, every patient requiring treatment should have a colposcopic examination to determine the transformation zone type and the presence or absence of precancerous or cancerous change.
- Excisional treatment is superior to destructive therapy because it facilitates histological examination of the transformation zone, whereby the diagnosis may be verified and margin status confirmed.
- Where excisional therapy is not available, destructive therapy is an entirely reasonable alternative to excision. When destructive therapy is used, the transformation zone should be of type 1 and small, and there should be no suspicion of invasive or glandular abnormality.
- Excisional therapy should always be performed under colposcopic vision, so as to achieve complete excision and minimize removal and damage of normal tissue. Some workers would advocate the same for ablative therapy, particularly where the transformation zone is larger than the probe tip and warrants overlapping application (e.g. using cold or thermal coagulation).